

Retrocaecal Hernia Causing Small Bowel Obstruction. A Case Report with Review of Literature.

A. Bendjaballah Md¹, Pr. M. Taieb², Dr. M.R. Oudjit³, Dr. S. Ammari⁴,
Pr. H Rabehi⁵, Dr. N. Nait Slimane⁶, Dr. R. Khiali⁷
^{1,2,3,4,5,6,7} Department of General Surgery Ain Taya Hospital - Algiers

Abstract: Internal hernias are rare causes of small bowel obstruction, and one such internal hernia is the paracecal hernia. **Paracecal** hernia is a rare type of internal hernia and, though congenital in origin, may occur at any age, usually with symptoms of acute intestinal obstruction. We report a case of a small bowel obstruction related to a paracecal hernia in which a preoperative diagnosis was made on computed tomography. A laparotomy was performed for definitive diagnosis and treatment. The surgery achieved a good outcome.

Keywords: Bowel obstruction; Internal hernia; Paracecal hernia, Small bowel, surgical treatment.

I. Introduction

Background: Small bowel obstruction caused by paracecal hernia is rare, and the condition is difficult to diagnose preoperatively. Internal hernias are relatively rare, and among these, paracecal hernia has been reported in only a few cases. An internal hernia (IH) is an infrequent cause of small bowel obstruction (SBO), with a reported autopsy incidence of 0.2 to 0.9%, and is the cause of small-bowel obstruction in 0.6 to 5.8% of the cases [1, 2]. Preoperative diagnosis of internal hernia is extremely difficult because of the nonspecific clinical presentation. Abdominal computed tomography (CT) plays an important role in the evaluation and management of patients with SBO. Urgent surgical intervention to prevent strangulation is essential. It is suggested that closure of these defects be performed if incidentally found at laparotomy. We are reporting a case of a SBO related to a retrocaecal hernia.

II. A Case Report

A 57 years old postmenopausal woman admitted in surgical department for small bowel obstruction for 2 days of evolution. There is no history of similar attacks in the past. She is followed and treated for systemic hypertension since 5 years. General and systemic examination of the patient was characterized by mild general conditions with no pallor, no jaundice and no lower limbs oedema. Examination of respiratory and cardiovascular systems revealed no abnormality. There was tenderness on examination of abdomen localized to the right iliac fossa and irradiating to all abdomen which was not distended. No palpable mass. no signs of abscess or general peritonitis. Blood exploration was within normal values except blood sugar which was slowly higher. Chest x-ray examination and ECG were without any abnormalities. Abdominal ultrasound examination shown a small bowel obstruction syndrome. CT scan of abdomen and pelvis shown: small bowel loops interposed between the cecum and the right abdominal wall with thickened wall, mesenteric vessels stretched and engorged converging toward the central region. This aspect is in favor of an internal retro caecal hernia. In front of the persistence of pain and continued vomiting the patient was taken immediately to the operating theater. the intraoperative exploration found a non-distended abdomen, a viable dilated ileal loops located under the cecum which is entirely free and the rest of the right colon that is not attached to the right parietocolic gutter. We performed a release of intestinal loops and the fixation of the right colon to the side wall of the abdomen. The patient had an uneventful 5-day hospitalization. She was discharged in good condition after recovery of normal intestinal transit.

III. Discussion

An internal hernia is defined as a protrusion of the abdominal viscera into one of the fossae, foramina, recesses, or congenital defects within the abdominal or pelvic cavity [1]. Intestinal obstruction caused by internal hernia is rare, with a reported incidence of up to 5.8% of all cases of intestinal obstruction [2]. Furthermore, paracecal hernia is very rare, and is responsible for only 0.1% to 6.6% of internal hernias [3,4]. Small bowel obstruction (SBO) caused by paracecal hernia is uncommon, and the condition is difficult to diagnose preoperatively. Internal hernias may infrequently cause SBO, which may be fatal because of the risk of strangulation of the hernial content. Paracecal hernias account for a minority of IH-related SBOs [5,6]. These hernias are the result of alterations in the normal process of intestinal rotation during embryonic development.

The embryological development of the cecum includes budding, exteriorization into the umbilicus and subsequent retraction onto the posterior abdominal wall, which usually predisposes the paracecal fossa to the formation of a number of pockets or recesses [7] Pericecal hernias constitutes 6-13% of all internal abdominal herniations [8-9].

Some mechanisms that may cause paracecal hernia have been suggested. One is that the hernial orifice is a congenital anatomic structure. The anatomy of the cecal and paracecal peritoneum is the end result of ileo cecal migration occurring during rotation of the midgut in the fifth month of gestation. The definitive pattern is attained after arrival of the cecum in the right iliac fossa and after fusion and resorption of the peritoneal surface, which have come, into apposition toward the end of the rotational process. Four kinds of peritoneal recesses of various depths occur in the paracecal area, namely the superior ileo cecal recess, inferior ileo cecal recess, retrocecal recess, and paracolic sulci, all of which may become hernial orifices [10]. Another possibility is that paracecal hernias are acquired by fragility due to aging, pressure elevation of the inner abdomen, adhesion of the retro peritoneum, and so on [11]. A classification for boundaries of hernias was formulated by Meyer [12,13], who described six: paracecal sulci, cecal fossa, cecal recess, superior ileo cecal recess, inferior ileo cecal recess, and retrocecal recess. Paracecal sulci are lateral depressions of the peritoneum invested on the cecum, but recesses may be absent. The cecal fossa is a groove that is formed by two peritoneal folds. The lateral fold is a continuation of the white line of Toldt and the medial fold originating from the ileo cecal angle, medial aspect of the cecum. The cecal recess is formed by folds described for the cecal fossa, but in this instance, the cecum is entirely retroperitoneal. Superior and inferior ileo cecal recesses are formed by a peritoneal fold originating from the terminal ileum to the cecum. A retrocecal recess is formed by the cecum anteriorly, the iliac fossa posteriorly, the right colic gutter laterally and the mesentery medially. The broad classification of internal hernias consist of paraduodenal (53%), pericaecal (13%), foramen of Winslow (8%), transmesenteric and transmesocolic (8%), intersigmoid (6%) and retroanastomotic (5%) [14]. There are many cases of internal hernias that have been reported in the literature [15, 16] but few cases of retrocecal hernias [17, 18, 19, 20, 21]. The clinical symptoms of internal abdominal hernias are nonspecific and include abdominal discomfort, recurrent episodes of intense abdominal pain and vomiting, acute small bowel obstruction with strangulation, or intermittent partial obstruction in chronic incarceration [22, 23, 24]. The symptoms caused by pericaecal hernia may be difficult to differentiate from appendiceal pain [24]; therefore, diagnosis is often difficult. Internal hernias (IH) have been rarely diagnosed preoperatively. The symptoms of an IH may be intermittent and nonspecific and it is a difficult diagnosis to make clinically or even with imaging. There are certain uncomplicated IHs, however, that can be diagnosed on CT with some degree of accuracy [25]; A precise and quick preoperative imaging diagnosis of internal abdominal hernias is mandatory because strangulation of the bowel loop may lead to ischemia and even gangrene in a short amount of time, thus increasing patient mortality rates. Delayed radiographs from a small bowel series or barium enema examination may reveal the obstruction site, but the procedures are time-consuming and cause further abdominal discomfort from the oral or anal insufflation of barium contrast medium [23]. CT is now considered the imaging modality of choice for the preoperative diagnosis of internal abdominal hernias [26, 27]. CT, especially MDCT, along with reformatted multiplanar coronal and sagittal images can be used for precise visualization of the abdominal anatomy, detection of the obstruction site, diagnosis of the cause of obstruction, and observation of the pathological conditions of the bowel wall, mesentery, and peritoneal cavity [28 29]. Pericecal hernia can be diagnosed with high certainty using contrast-enhanced CT. The CT appearances of the congenital and acquired types of pericaecal hernias are similar and very specific: a cluster of encapsulated and fluid-filled dilated or edematous small bowel loops seen lateral to the anteromedially displaced cecum and ascending colon, displaced mesenteric vessels within the hernial sac, a beaking appearance at the entrance of the hernia, and a dilated afferent small bowel loop and collapsed efferent loop in the transition zone. The first CT sign was present in all reported cases to date [28,30,29,24]. CT allows advanced diagnosis of intestinal obstruction because it provides more information about the cause than do either X-ray or contrast studies. In addition to demonstrating the presence of extraluminal lesions, such as masses, adenopathy, soft tissue infiltration, fluid collections, abscesses and vascular anomalies, the greatest advantage of CT is the diagnosis of early or partial obstruction, closed loop obstruction and multiple segments of obstruction [31,32]. Dilatation of small intestine loops with a transitional zone adjacent to the cecum or an edematous small bowel located lateral to the cecum allows a paracecal hernia to be diagnosed with high certainty [33]. In the case described by Bharatam et al, a CT scan of a young man presenting with a transmesenteric hernia detected this hernia although it did not show SBO [34]. Mehra & Pujahari's description of two cases of paraduodenal hernias did not use CT in their diagnostic work up, instead opting for Abdominal X-Ray, followed by laparotomy in the first case and a barium swallow followed by laparotomy in the second [35]. In your patient the diagnosis of retrocecal internal hernia was made by CT scan which was a considerable contribution. Early surgical intervention is mandatory in these cases because treatment delays may result in bowel ischemia or even necrosis, leading to high patient morbidity and mortality rates [36,37]. The operation for intestinal obstruction is usually performed with a wide incision at the surgical site.

Some literatures about laparoscopic management of acute small bowel obstruction were published. The literatures said that the diagnostic accuracy of laparoscopy was high (60–96.9%), formal laparotomy was avoided in about 70% of patients, and the return of bowel function and postoperative stay was reduced [38,40]. Kirshtein et al. described that minimally invasive and reduced-access approaches were totally successful by the laparoscopic management [39]. And Al-Mulhim emphasized that conversion must not be considered a “failure” but a “safe” extension of laparoscopic procedure [40]. There are two reports of paracecal hernia treated by laparoscopy only [41]. Our patient was managed by median laparotomy.

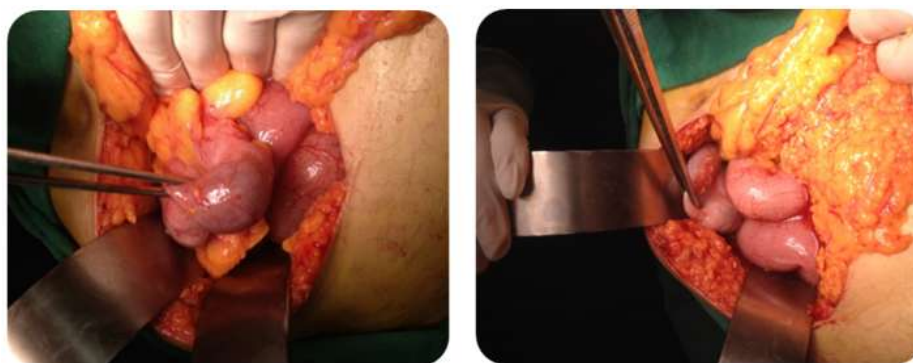IV. Conclusion

Pericecal hernia is a relatively uncommon form of internal hernia. Early preoperative recognition and specific CT signs of the pericecal hernia may prompt immediate surgical operation to reduce patient mortality and morbidity rates. Actually laparoscopic approach can be used as treatment of internal hernia with or without associated bowel obstructions.

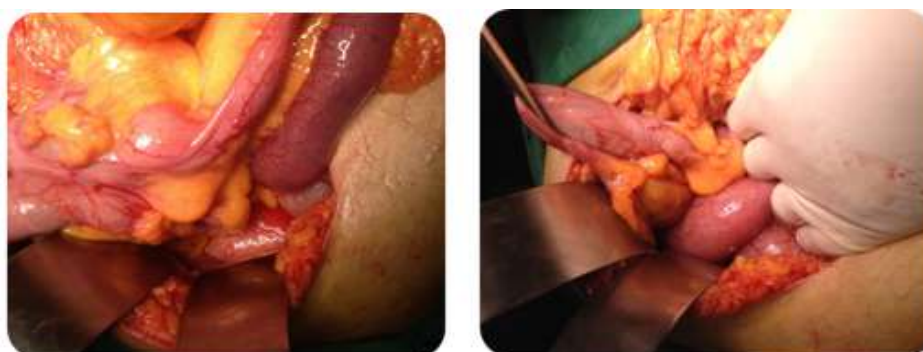
References

- [1]. Osadchy A, Keidar A, Zissin R: Small bowel obstruction due to a paracecal hernia: computerized tomography diagnosis. *Emerg Radiol*, 2005; 11: 239–41
- [2]. Blachar A, Federle MP: Internal hernia: an increasingly common cause of small bowel obstruction. *Semin Ultrasound CT MR*, 2002; 23: 174–83
- [3]. Bass J Jr, Longley BJ: Paracecal hernia: case report and review of the literature. *Am Surg*, 1976; 42: 285–88
- [4]. Rosen L, Woldenberg D, Friedman IH: Small bowel obstruction secondary to pericecal hernia. *Dis Colon Rectum*, 1981; 24: 45–46
- [5]. Ghahremani GG. Internal abdominal hernias. *Surg Clin North Am* 1984;64:393–406
- [6]. Leffall LD Jr, Quander J, Syphax B. Strangulation intestinal obstruction. *Arch Surg* 1965;91:592–596.
- [7]. Omori H, Asahi H, Inoue Y, Irinoda T, Saito K. Laparoscopic paracecal hernia repair. *J Laparoendosc Adv Surg Tech A* 2003;13:55–57.
- [8]. Rivkind AI, Shiloni E, Muggia-Sullam M, Weiss Y, Lax E, Freund HR. Paracecal hernia: a cause of intestinal obstruction. *Dis Colon Rectum* 1986;29:752–754.
- [9]. Schumpelick V, Dreuw B, Ophoff K, Prescher A. Appendix and cecum. Embryology, anatomy, and surgical applications. *Surg Clin North Am* 2000;80:295–318
- [10]. Yamamoto A, Marukawa T, Eguchi T: A Case of Retrocecal Hernia. *Geka Sinryou* 1993; 51: 595–97 (in Japanese)
- [11]. Meyer A, Nowotony K, Poeschl M. Internal hernias of the ileocecal region. *Ergeb Chir Orthop* 1963;44:176–204.
- [12]. Meyer A, Nowotony K, Poeschl M. Internal hernias of the ileocecal region. *Ergeb Chir Orthop* 1963;44:176–204.
- [13]. Bass J Jr, Longley BJ. Paracecal hernia: case report and review of the literature. *Am Surg* 1976;42:285–288..
- [14]. Meyer A, Nowotony K, Poeschl M. Internal hernias of the ileocaecal region *Ergeb Chir Orthop*. 1963; 44: 176-204
- [15]. Bharatam KK, Kaliyappa C, Reddy RR. Right sided transmesenteric hernia: A rare cause of acute abdomen in adults. *Int J Surg Case Rep*. 2014; 5(12): 1154- 7.
- [16]. Mehra R, Pujahari AK. Right paraduodenal hernia: report of two cases and review of literature. *Gastroenterol Rep (Oxf)*. 2014 Nov 6
- [17]. Lindsey I, Nottle PD. Laparoscopic management of small bowel obstruction caused by retrocaecal hernia. *Surg laparosc Endoc*. 1997 Aug;7(4):349-50.
- [18]. Paron L, Peirano M, Sacco D, Cardino L. Intestinal occlusion caused by internal hernia of the retrocaecal recess. Description of a case. *Minerva Chir*. 1993 Jul;48(13-14):801-2
- [19]. Dhillon A, Farid SG, Dixon S, Evans J. Right salpingo-ovarian and distal ileal entrapment within a paracaecal hernia presenting as acute appendicitis. *Int J Surg case rep*. 2013;4(12):1127-9.
- [20]. Singh LM, Yedalwar V. Retrocaecal hernia: A rare cause of small bowel obstruction. *Journ Evol Med & Dent Sci*. 2014. 3(20): 5509-5512.
- [21]. Cerrahi G. A rare cause of mechanical intestinal obstruction: Primary internal pericecal hernia. 2014. *CausaPedia* 4; 3: 726.
- [22]. Fu CY, Chang WC, Lu HE, et al. Pericecal hernia of the inferior ileocecal recess: CT findings. *Abdom Imaging* 2007; 32: 81-8397-1015
- [23]. Mathieu D, Luciani A. Internal abdominal herniations. *AJR Am J Roentgenol* 2004; 183: 397-404
- [24]. Takeyama N, Gokan T, Ohgiya Y, et al. CT of internal hernias. *Radiographics* 2005; 25: 9

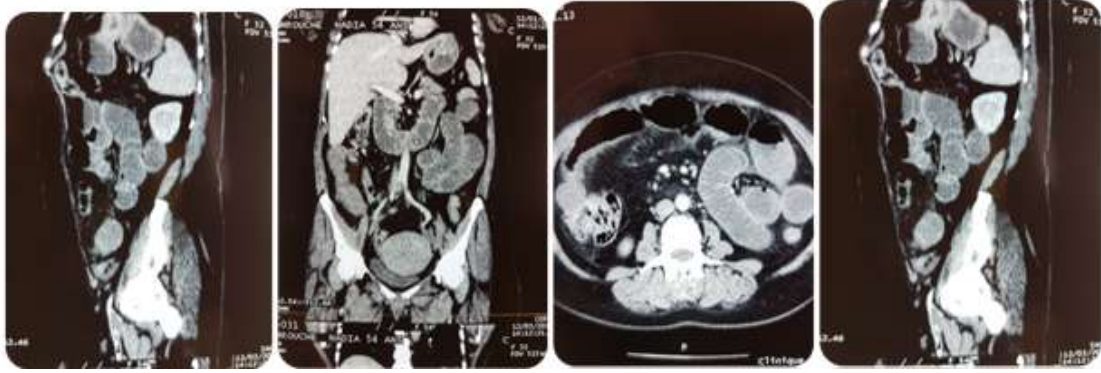- [25]. Blachar A, Federle MP, Dodson SF. Internal hernia: clinical and imaging finding in 17 patients with emphasis on CT criteria. *Radiology* 2001; **74**: 218-68
- [26]. Mathieu D, Luciani A. Internal abdominal herniations. *AJR Am J Roentgenol* 2004; **183**: 397-404
- [27]. Takeyama N, Gokan T, Ohgiya Y, et al. CT of internal hernias. *Radiographics* 2005; **25**: 9
- [28]. Fu CY, Chang WC, Lu HE, et al. Pericecal hernia of the inferior ileocecal recess: CT findings. *Abdom Imaging* 2007; **32**: 81-83
- [29]. Jang EJ, Cho SH, Kim DD. A case of small bowel obstruction due to a paracecal hernia. *J Korean Soc Coloproctol* 2011; **27**: 41-43
- [30]. Lassandro F, Iasiello F, Osadchy A, Keidar A, Zissin R. Small bowel obstruction due to a paracecal hernia: computerized tomography diagnosis. *Emerg Radiol* 2005; **11**: 239-241.
- [31]. Furukawa A, Yamasaki M, Furuichi K, Yokoyama K, Nagata T, Takahashi M, et al. Helical CT in the diagnosis of small bowel obstruction. *Radiographics* 2001; **21**: 341-355.
- [32]. Boudiaf M, Soyer P, Terem C, Pelage JP, Maissiat E, Rymer R. CT evaluation of small bowel obstruction. *Radiographics* 2001; **21**: 613-624.
- [33]. Martin LC, Merkle EM, Thompson WM. Review of Internal hernias: Radiographic and clinical findings. *AJR*. 2006; **186**: 703-717.
- [34]. Bharatam KK, Kaliyappa C, Reddy RR. Right sided transmesenteric hernia: A rare cause of acute abdomen in adults. *Int J Surg Case Rep*. 2014; **5**(12): 1154- 7.
- [35]. Mehra R, Pujahari AK. Right paraduodenal hernia: report of two cases and review of literature. *Gastroenterol Rep (Oxf)*. 2014 Nov **6**.
- [36]. Fu CY, Chang WC, Lu HE, et al. Pericecal hernia of the inferior ileocecal recess: CT findings. *Abdom Imaging* 2007; **32**: 81-83
- [37]. Jang EJ, Cho SH, Kim DD. A case of small bowel obstruction due to a paracecal hernia. *J Korean Soc Coloproctol* 2011; **27**: 41-43
- [38]. Strickland P, Lourie DJ, Suddleson EA et al: Is laparoscopy safe and effective for treatment of acute small-bowel obstruction? *Surg Endosc*, 1999; **13**: 695-98
- [39]. Kirshtein B, Roy-Shapira A, Lantsberg L et al: Laparoscopic management of acute small bowel obstruction. *Surg Endosc*, 2005; **19**: 464-67
- [40]. Al-Mulhim AA: Laparoscopic management of acute small bowel obstruction Experience from a Saudi teaching hospital. *Surg Endosc*, 2000; **14**: 157-60
- [41]. Omori H, Asahi H, Inoue Y et al: Laparoscopic paracecal hernia repair *J Laparoendosc Adv Surg Tech A*, 2003; **13**: 55-57



Photos 1 & 2: showing herniated loops in retrocecal recesses



Photos 3 & 4: shown dilated and strangulated terminal ileum herniated under totally free cecum and right colon



Photos 5,6,7,8 shown: small bowel loops interpolated between the free cecum and the right abdominal wall. Mesenteric vessels stretched and engorged converging toward the central region. This aspect is in favor of an internal retro cecal hernia.